

“Conceptual Study of Malashay with Special Reference to Rectum ”

**Dr. Soniya M. Dahat¹, Dr. Nitin S. Chandurkar², Dr. Pavan R. Gulhane³,
Dr. Rupali R. Bawa⁴, Dr. Amar S. Kamble⁵, Dr. Leena G. Jungade⁶**

¹MD- Scholar , ²Professor & HOD , ³Assistant Professor , ⁴Associate Professor, ⁵PhD Scholar, ⁶Assistant Professor of RachanaSharir Department, Dr. D. Y. Patil College of Ayurved& Research Centre, Pimpri, Pune, Dr. D.Y. Patil Vidyapeeth, Pune .

ABSTRACT:-

In Ayurveda, RachanaSharir is the branch of science where detailed study of human body & description of structure studied, there are many concepts explained by Acharyas, the one of them is Ashaya. Ashaya are considered as *AshayoAdhishthanam*. *Ashaya* means hollow space in the particular structure in our body or viscera, having capacity to provide accommodation to the important constituent of the body like Dosh, Dhātu, Anna, Mala, Mutra, Garbha etc. & they named accordingly as *vatashaya* , *pittashaya*, *shleshmashaya*, *Aamashya* , *Pakwashaya*, *Mutrashaya*, *Garbhashaya* . AcharyaSushrut, Vagbhat& other Acharya considered pakwashaya as the sthan of pakwaanna; where mala is remain with pakwaanna. So they do not explain separate ashaya for mala. But Acharyasharangadhar consider the ashaya for mala & they named it as *malashaya*. The third member of the trinity of the living body is Mala. The faeces (stool) / Puish is the part of mala which is also known as "vit". Here in this study the Mala is considered as the undigested residue left over after the nutrient fraction of the food which has been separated and absorbed. After complete conversion into mala the *malashaya* is the place where mala is reside until it is not defecated out & that place can be studied with the help of anatomy and physiology literature. Hence the present study can be used in understanding exact *adhishthan* of mala, which is beneficial for knowing the root cause or pathogenesis of any diseases or vyadhi with reference to rectum and treat them accordingly.

Key words: - Ashaya, Adhishthan, Malashaya, Rectum.

INTRODUCTION:-

Ayurveda has its own fundamental concepts explained in samhitas. For better understanding of samhitas every concepts, the conflict about the concepts or terminology mentioned in samhitas related to anatomy need to be clarified.

The concept of Ashaya[1] is explained by different Acharyas in various samhitas . Ashaya means hollow space in the particular structure in our body or viscera, having capacity to provide accommodation to the important constituent of the body like Dosh, Dhātu, Anna, Mala, Mutra, and Garbha etc. There are seven types of ashaya explained by acharyas& they named according to the entities present into it as for Vata, the Ashaya is *Vatashaya*, for Pitta, the Ashaya is *Pittashaya*, For kapha, the Ashaya is *Shleshmashaya*, For Rakta, the Ashaya is *Raktashaya*, for Aamanna means partly digested food, the Ashaya is *Amashya*, For Pakwaanna i.e. for digested food *Pakwashaya*, for MutraAshaya is *Mutrashaya*. But in Female one more Ashaya is present which is *Garbhashaya* where Garbha is reside till Prasav.

During the process of Digestion (Pachana) of food , the food is get converted into Ahar rasa , this ahar rasa is the saarbhaḡ of food which is absorbed by the body for nourishment in small intestinal part of body & after absorption of saarbhaḡ the kittabhaḡ is formed . Kittabhaḡ is again going into differentiation to form Purish and Mutra. The part of kittabhaḡ i.e. Purish which is the remnant of pakwaann will remains in *Pakwashaya* i.e. Large intestine, So there is no separate explanation of Ashaya for purisha , but there is need to explain separate ashaya for mala as mala represents the part of the undigested residue left over after the separation &

absorption of nutrient fraction from the food . This purnatva for mala is get into the rectum part, so ashaya for mala i.e. *malashya* can be considered with the Rectum.

AIM:-

Study of Malashaya with special Reference Rectum.

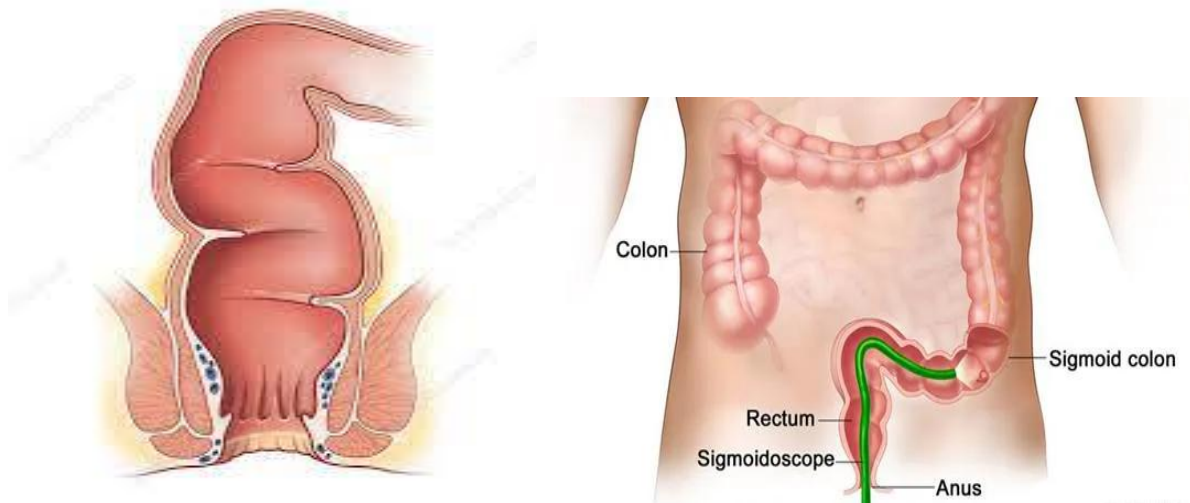
OBJECTIVE:-

1. To study the Ashay from Ayurvedic samhitas.
2. To study *Malashaya* & Rectum from Ayurvedic science & modern science.
3. To establish the malashaya as Rectum part of body.

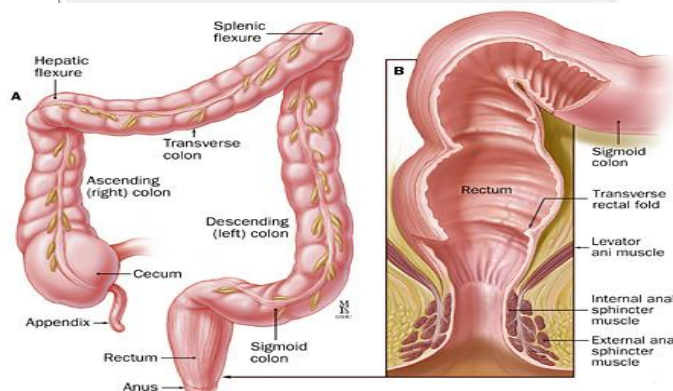
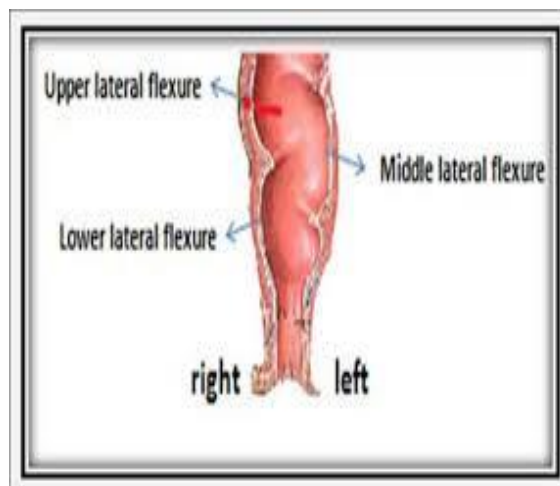
Anatomy & Physiology of rectum:-

Rectum[2] is the distal part of the large Intestine, placed between sigmoid colon above & anal canal below. It is situated in lessor part of pelvis, in front of lower three pieces of the sacrum & coccyx.

It is about 12 cm long, in the upper part it has same diameter of 4 am as that of sigmoid colon, but in lower part it is dilated to form rectal ampulla. It is not straight in man it is curved in an anteroposterior direction & also from side to side. Rectum shows two types of curvatures in the course:-



- i) Two anteroposterior curvature:-
 - a) The sacral flexure of the rectum follows the concavity of the scrum & coccyx.
 - b) The perineal floor of the rectum is the backward bends at the anorectal junction.
- ii) Three lateral curves:-
 - a) The upper lateral curve of Rectum is convex to the right.
 - b) The middle lateral curve is convex to the left & is most prominent.
 - c) The lower lateral curve is also convex to the right, like upper lateral curve.

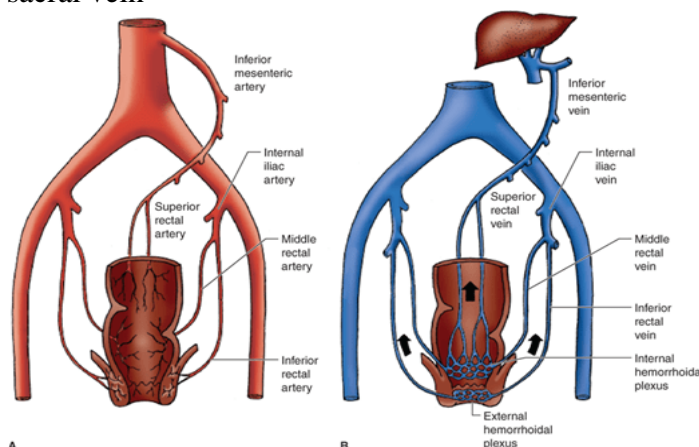


Arterial supply to Rectum:-

- 1) Superior rectal artery
- 2) Middle rectal artery
- 3) Median sacral artery

Venous Drainage from Rectum:-

- 1) Superior rectal vein: - The Tributaries of the vein continuous with Inferior mesenteric vein which ends into the splenic vein, this splenic vein drain into the portal vein, which carries the nutrients rich blood towards the liver.
- 2) Middle rectal vein
- 3) Median sacral vein



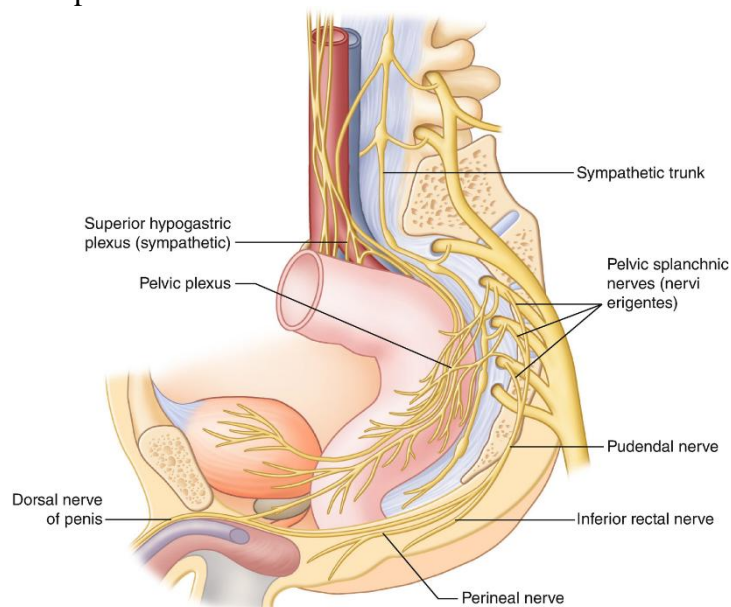
Lymphatic Drainage of the Rectum:-

- 1) Lymphatic from upper half of the Rectum passes through perirectal & sigmoid nodes.

- 2) Lymphatics from lower half of rectum passes through internal iliac nodes.
- 3) Lymphatics from lower part of anal canal drain into superficial inguinal lymph nodes.

Nerve supply to the rectum:-

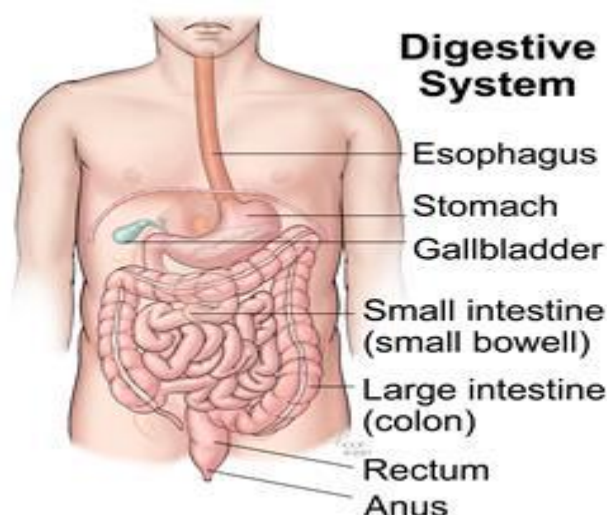Rectum is supplied by both Sympathetic (L1, L2) & Parasympathetic (S2, S3, S4), nerve through the superior rectal, or inferior mesenteric & inferior hypogastric plexuses



Rectum has mainly three main functions i.e. absorption, storage & transportation. It receives stool from the colon it act as a temporary storage site for faeces, it take part in holding the stool until evacuation happens. When faecal material received by the Rectum is in small quantity, it is stored in the rectum for some time but when the volume of faecal material is big it affects the rectal distension sufficient to initiate the defecation reflex. when stool / kittabhag came into rectum sensory massage from sensory reflexes send to Brain ,then Brain sends the motor Reflex to Sphincter part of Rectum that sphincter reflex decide whether the rectal content to be released or not . If the sphincter is in relax state, there is contracts of rectum & it dispose rectal contents. And if the sphincter is in contract state then the Rectal contents cannot be disposed, rectum accommodates that content so that the sensation of defecation temporarily goes away.

Process of Digestion:-

Digestion[3] is the process by which food is broken down into simple chemical substance that can be absorbed & used as nutrients by the body. The process of digestion is carried out by digestive system which is made up of gastrointestinal tract or alimentary canal & accessory organs (pancreas, liver gallbladder, teeth, and tongue) which helps in the process of digestion & absorption



The Activity of digestive system can be grouped under following headings:-

1. Ingestion: - Ingestion is process of eating or drinking of food into the alimentary tract.
2. Propulsion: - in this there is mixing & movements of food along the alimentary tract.
3. Digestion:- Digestion is the process where break down of food takes place & it can be done by two type of process i.e. by mechanical digestion (break down of food e.g. mastication) & by chemical digestion (breakdown of food by enzymes produced by digestive glands)
4. Absorption: - Absorption process is takes place in alimentary canal digested food substance when passes through the walls of alimentary canal they get absorbed by blood & lymph capillaries.
5. Elimination: - after absorption the remaining undigested & unabsorbed substance are excreted from the alimentary canal in the form of faeces by process of defaecation.

The main Mechanism of digestion includes: - mechanical digestion, chemical digestion. Absorption & Defaecation.

1. Mechanical digestion:- it includes Mastication process cause by chewing action of teeth, Swallowing process in which food is swallowed, Churning in Stomach in which wall of the stomach undergoes periodic movements which help in breakdown of complex food into simple form.
2. Chemical digestion: - it involves the breaking of covalent chemical molecules like carbohydrate, proteins, and lipids by Digestive Enzymes.
3. Absorption: - absorption is the process where the end product of digested food is absorbed by the blood or lymph through intestinal mucosa .The small intestine is the structured of body where maximizing nutrient absorption takes place. The digested nutrients via diffusion or special transport proteins pass through the absorptive cells of the intestine The transportation of Amino acids, minerals, alcohol, water soluble vitamins, and monosaccharides (sugars like glucose) takes place from the intestinal cells into capillaries, & the larger emulsified fatty acids, fat-soluble vitamins, and other lipids are transported into blood vessels from lymphatic vessels . The digestion process is fairly efficient process. The food which is not fully broken down or the indigestible food fibre content moves from the small intestine to the large intestine (colon) through a connecting valve i.e. ileocecal sphincter. In the large intestine there is no digestion of food takes place, only the main role of large intestine is to reabsorb water, minerals such as sodium, potassium. & this reabsorption is important to conserve the water in body. Also there are large number of bacteria residing in the large intestine, The majority of bacteria present in large intestine are harmless and some of them are beneficial & this bacteria help in synthesizing the essential

nutrient, vitamin K, short chain fatty acids, which are essential for our health, from the undigested fibre.

4. Defaecation: The Defaecation is the Voluntary process, the process is caused by peristaltic movements, the digestive wastes, solidified into coherent faeces & through neural reflex in Rectum cause an urge or desire for its removal.

Discussion:-

AcharyaSharangdharexplain the concept of *malashaya* as the Ashaya where mala is reside. During the process of Digestion of food (Ahara), the food is get converted into two stages i.e. *Aamavastha*&*pakvastha*. *Aamavastha* is the stage when food (ahar) is converted into partly digested food & this process takes place in *Amashaya*. *Pakvastha* is the stage when food (Ahar) is converted into fully digested food i.e. pakwaann , after complete Digestion (Pachan) of food , Ahar Rasa then converted into Saar bhag&Kittabhag this saarkittavibhajan takes place in unduk part i.e. caecum part of intestine. Saar bhag is absorbed by the body for nourishment from small intestine which is above the caecum part. Kittabhag is came into unduk part where it again divide into mutrabhag&purishbhaag. For mutra there is separate ashaya which is *Mutrashaya*. But *Purishbhag* is move along the large intestine to reaches up to Rectum & from Rectum is get defecated out through anal canal.

The purishbhag which is in large intestine is the Purishbhag along with water & remaining absorbable nutrients of the food & their absorption takes place in large intestine, it is not in complete (purnaswaroop) stage of mala , when it reaches to the Rectum part of intestine it got the completeness / purnaswaroop as a mala . So Rectum is the part of body where complete (purnatva / purnaswaroop) for mala get, &, where mala is reside in small volume, until a big volume accumulated, when big volume of mala comes into Rectum it affect the rectal distension & initiate the defecation reflex. I.e. when stool (mala) receive from sigmoid colon is remain in Rectum part if it is in small quantity but when the adequate volume reached into rectum it stimulate the mechanoreceptors which causes evokes of Recto- anal inhibitory reflex, Rectum act as storage organ for stool. The stool present in the rectum may affect its consistency & help as a contributing factor in the genesis of constipation, so site for *malashaya* is the Rectum Part of large intestine.

Acharyasharangdhar giving the location of *malashaya* said that; *pawanashaya* is present below the amashaya, &malshaya is situated below the *pawanashaya*, *pawanashaya* means where Pawan i.e. vata is situated & main site for vata is *ispakwashaya* so *pakwashaya* is the main site for vata, &*malshaya* is present below to *pawanashaya* which can be correlated with the rectum part i.e. the site of mala.

AcharyaCharak while explaining the 15 koshtanga in sharirsthan out of them *puishdharascha* i.e. where purish is hold means the place where Purish is situated is the site of Rectum Part i.e. *malashaya* part of large intestine.

From Physiological point of view ,from ileocecal junction almost 350 gm of kittabhag is came into the caecum but after passing to the part of large intestine i.e. Ascending colon, Transverse colon, Descending Colon, colic flexor, sigmoid colon part when it came in Rectum the weight of Kittabhag is almost 135 gm , which shows after coming into caecum part & large intestinal part kittabhag is not in prunaswaroop of mala , still there is some constituents like electrolytes ,organic substance etc. which is absorbed by body & when reaches to rectum Part it get purnaswaroop to mala .

The venous drainage of the large intestine up to the upper part of the rectum is from superior rectal vein, which drain its blood into Inferior mesenteric vein. The inferior mesenteric vein ends in splenic vein, the splenic vein drain their venous blood into Portal vein. Portal vein is

the vein which carries nutrients Rich Blood towards the Liver. The blood supply of Liver is 20% by hepatic artery which carries Oxygenated blood, & 80% from portal vein which contain nutrients Rich blood. Up to the upper part of rectum, it drain their blood from superior rectal vein into splenic vein & ultimately into portal vein which indicate up to this part still there is nutrients rich content present which is absorbed by the bloods, before it get converted into stool (mala).

Rectum has apparently three main functions absorption, storage & transportation. If the faecal material received by the Rectum is in small quantity, it is stored in the rectum until but when the volume of faecal matter is large amount it affects the rectal distension sufficient to initiate the defecation reflex.

Conclusion:-

From above discussion *Ashaya* is the hollow space in the particular structure in our body or viscera, having capacity to provide accommodation to the important constituent of the body. *Ashaya* for mala can be considered as Rectum (*malashaya*). Rectum is the part where completeness (purnatva / purnaswaroop) to the mala occurs. Until to the rectum, food is not fully digested and also it contains the essential elements which needs to be absorbed by the body. This process of absorption continues till the upper part of the rectum after that there is not the chances of absorption. So, we can say that here the ahar rasa get its purnatva as to be called as mala and where it is stored i.e. rectum part as a *malashaya*. So, by all the description one can conclude that rectum should be called as *malashaya*. This study is important, As Mala is also the important constituents, if any abnormality in mala can leads to disease in body so if we know the exact location of mala then it is very easy for physician to know its pathogenesis & to treat it.

ACKNOWLEDGEMENT:-

I would like to express my gratitude to my Guide Professor Dr. Nitin S. Chandurkar sir, HOD of RachanaSharir Department, all Teaching staff & colleagues of RachanaSharir department of Dr. D. Y. Patil Ayurved College & Research Centre, Pimpri, Pune of Dr. D.Y. Patil Vidyapeeth Pune, who guided me throughout this article work.

References:-

- [1] S. S. Umesh and S. U. Vasant, "CONCEPTUAL STUDY OF ASHAYA WITH SPECIAL REFERENCE TO SUSHRUTA SAMHITA," vol. 2, no. 4, p. 7.
- [2] "Rectum | anatomy | Britannica." <https://www.britannica.com/science/rectum> (accessed Jun. 11, 2021).
- [3] "Digestion: Anatomy, physiology, and chemistry," Jan. 11, 2018. <https://www.medicalnewstoday.com/articles/320014> (accessed Jun. 11, 2021).
- [4] SarangadharSamhita, Dr. BhramanandTripathi, chouxhambhasurabharatiprakashana reprint 2004, page no.54, sharir parichay chapter 5th
- [5] SarangadharDarpan, Dr. BhugupatiPandeya, chouxhambaorientalia Varanasi reprint 2012, page no 145, Garbhotpatti chapter 2nd
- [6] SarangadharSamhita, by Dr. K.R. Srikantha Murthy, chouxhambaorientalia Varanasi 2012, page no 21, KaladikakhyanaShariram chapter 5th.
- [7] SarangadharSamhita, AcharyaPanditSarangadharacharya, chouxhambaorientalia Varanasi edition 2002, page no 44, prathamkhand aa.5, Saptadhatuvivaranam, adhaya 5.
- [8] CharakSamhita, Dr. BramhanandTripathi, chouxhambasurbhartiprakashan Varanasi edition 2006, page no.924, sharirsthansharirsankhyasharirdhyaya 5th.

- [9] SushrutaSamhitaDalhanaAcharyavirachitaNibhandhasangrahasavyakhyavaidyaYadavajiTri kamajiacharyachoukhambhasurabharatiprakashana reprint 2012. Page no: 364, Sharirsthana chapter 5, verse no 8.
- [10] SushrutaSamhitaDalhanaAcharyavirachitaNibhandhasangrahasavyakhyavaidyaYadavajiTri kamajiacharyachoukhambhasurabharatiprakashana reprint 2012. Page no: 99, Sutra sthana chapter 21, verse no 3.
- [11] SushrutaSamhitaDalhanaAcharyavirachitaNibhandhasangrahasavyakhyavaidyaYadavajiTri kamajiacharyachoukhambhasurabharatiprakashana reprint 2012. Page no: 257, Nidansthana chapter 1, verse no 8.
- [12] SushrutaSamhitaDalhanaAcharyavirachitaNibhandhasangrahasavyakhyavaidyaYadavajiTri kamajiacharyachoukhambhasurabharatiprakashana reprint 2012. Page no: 102, Sutra sthana chapter 21, verse no 16.
- [13] SushrutaSamhitaDalhanaAcharyavirachitaNibhandhasangrahasavyakhyavaidyaYadavajiTri kamajiacharyachoukhambhasurabharatiprakashana reprint 2012. Page no: 279, Nidansthana chapter 3, verse no 21.
- [14] AstangaSamgrahaAcharyaVagbhatavirachita, KavirajAtridev Gupta choukhambakrishanadas academy Varanasi reprint 2016 page no.302, Sharirsthan chapter5/46. 13.
- [15] B.D. chaurasia human anatomy volume 4th , , CBS Publishers & Distributors Pvt Ltd; New Delhi 2010, Vol 2, Chapter33 page 409.
- [16] Textbook of Ayurved anatomy by prof. C.R. Agnives, Hareesree publication first edition 2015, page no. 185 , koshtaevamAshayashariram chapter 9th
- [17] Text book of sharirkriyavigyan- human physiology prof. Purnachandra Jain, & Dr. PramodMalviya.
- [18] Hall. E, Guyton. C. Gastrointestinal physiology, Textbook of medical physiology, New Delhi (India), Elsevier; 2016. p. 776.
- [19] Krishna Garg, B D Chaurasia's Human Anatomy, 5th edition, CBS Publishers & Distributors Pvt Ltd; New Delhi 2010, Vol 2, Chapter33 page 409
- [20] Hall. E, Guyton. C. Gastrointestinal physiology, Textbook of medical physiology, New Delhi (India), Elsevier; 2016. p. 776.