

Comparative Study between the Effect of Apricot Seeds Extract and Gentamicine Ointment on Corneal Healing After Induced Ulcer in Eye Cornea in Pigeons

Rana K. Abdulsamad¹, Aseel K. Hameed², Jinan Abdul. K Hilal³,
Ibrahim MH AL Rashid¹

¹College of Veterinary Medicine Department of Surgery and Obstetrics, University of Basrah, Basrah, Iraq.

²College of Dentistry, Department of Basic Science, University of Basrah, Basrah, Iraq.

³ College of Veterinary Medicine Department of Physiology, University of Basrah, Basrah, Iraq.

Correspondence Author Email: ibrahim.muhammad@uobasrah.edu.iq

Abstract

The present study was showed excellent healing of Apricot seed extract of eye corneal ulcer of pigeons compare with control and gentamicine groups. Apricot seed extract which composite many biochemical components have bioactive to recover and heal ulceration of the cornea. Cornea is a connective tissue to have collagen and fibers and the defect of cornea therefore the recovery is slow. The Apricot seed extract group showed good healing of corneal ulcer that evident the extract have good bioactive component assist in healing compare two groups. Histopathological images reveal to excellent healing. In conclusion the Apricot seed extract is an excellent agent to treat eye, corneal ulcer in pigeons and other animals. Gentamicine shows improvement in corneal ulcer through increasing the vascularization and infiltration of cells; also it causes an increase in congestion in blood vessels but increases thickness epithelium while the apricot group shows thick corneal epithelium related with inflammatory cells. These findings indicate that apricot was good in treating for eye ulcer.

Key words: ulcer, apricot seed, Gentamicine , pigeons

Introduction

Apricot seeds are found at the middle of the apricot fruit (*Prunus armeniaca*), which is considered a stone fruit. Whenever you eat an apricot, you will eventually reach the pit at the center of the fruit, and the seed (or kernel) is found within the shell of that pit. These seeds are some debate, as they contain some unique compounds, some of which have powerful effects on human health but may also pose a significant harm. Most notably, apricot seeds contain vitamin B17, more commonly known as amygdalin or laetrile which studies have shown can have anti-cancer and anti-inflammatory properties (Chen Y et al., 2016). The fruit is found to be rich source of carbohydrates (both mono and polysaccharides) (Doganay et al., 2013), polyphenols 13-14, carotenoids (β -carotene) (Ebtahal, 2011), vitamins C and K, thiamine (Thia), niacin (Nia), iron, organic acids, phenols, and volatile compounds. benzaldehyde, esters, norisoprenoids, and terpenoids (Nout et al., 1995). The apricot is reported to contain a cyanogenic glycoside amygdalin (vitamin B17) due to which if eaten they are hydrolyzed by enzyme β -glucuronidase in alkaline environment of small intestine into glucose, benzaldehyde, and hydrocyanic acid and with emulsification, it is absorbed quickly and circulates in the body and thus can be responsible for its toxic effects. This is more common in man due to man's lower body mass and thus man's high gastric acidity than that of children. Ripe fruit pulp contains total solids (12.4 – 16.7%), insoluble solids (2.1 – 3.1%), acids as malic acid (0.7-2.2%), total sugar as invert sugar (5.3-8.6%), glucose (3.2-4.8%), fructose (1.4-4.25%), sucrose (1.4-5.4%) and tannins (0.06- 0.10%) (Erdogan et al. 2010).

Corneal endothelial decompensation leads to blurred vision and is comfort or even severe pain. Medical treatment can be used to relieve symptoms, the only definitive treatment for corneal

endothelial dysfunction is corneal transplantation, which can be performed in the form of full-thickness penetrating keratoplasty (PK)(Feizi, 2018). The transparent cornea is the outer layer of the eye at the front. Harderian gland coats the cornea and prevents dryness. Crampton's muscles can change the shape of the cornea, thus giving birds a greater range of accommodation than is possible for mammals. In addition, ciliary muscle altering the corneal fissure for corneal accommodation and moving the ciliary body anteriorly as a part of the lenticular accommodative mechanism (Shehan, 2012). This transparency is associated with the exceptional regularity of the protein content of the corneal stroma and the relative rarity of cells packed with organelles that would otherwise diffract light. The protein is of course collagen fibrils, each of them the same diameter, spaced equally apart by a similar distance. The regularity of the collagen fibrils that provide the cornea with its structural integrity render them 'invisible' to the light rays passing through them. 'Invisible' as long as their regularity is maintained (Kang, 2020). Cornea basically consists of five layers namely epithelium, Bowman's layer, stroma, Descemet's membrane and the endothelium. It is one of the few avascular tissues in the body. The normal healthy cornea does not have any blood vessels(Georgiadis, et al. 2008). The anterior ciliary artery derived from the ophthalmic artery forms an arcade at the limbus (Chipuk et al., 2010). The cornea has a protective epithelium, a dense collagenous stroma lined by an endothelium giving a tough resilient structure. It is transparent (Domitrovic et al., 2014). Important physiology of cornea in the eye include protecting the structures inside the eye, contributing to the refractive power of the eye, and focusing light rays on the retina with minimum scatter and optical degradation (Nostro et al., 2000). Cornea along with conjunctiva and tear film acts as a major component of ocular defense system against the microbial infections. While corneal epithelium acts as a mechanical strong barrier, the cellular and chemical components of conjunctiva and precorneal tear film act as biologic protective systems (Lee et al., 2014). Corneal ulcers can range from small epithelial erosions that will heal in less than a week, to a descemetocoele that may rupture by the end of the day. Treatment of such varied lesions depends on a correct assessment of how deep the ulcer is and whether it is in the process of healing (Kim et al., 2016). The avian corneal epithelium, like that of humans, has a true Bowman's layer. It has been theorized that the distinguishing of this layer after a blunt abrasive trauma may have an impact on corneal epithelialization, which is not apparent in mammal species (Yau, et al. 1986). A sterile corneal ulcer may occur due to systemic dermatologic or connective tissue disease and chemical or thermal injuries(Feizi, 2018).

Materials and Methods

Twelve adult pigeons were used in this study. The birds were clinically healthy and stay in the cages at animal house, College of Veterinary Medicine, University of Basrah. Food and water were given freely during the adaptation period. The experiment was carried out on one eye of each animal.

Induce Ulcer

A round 5-mm diameter circular filter paper disk produced by standard paper bunch, this filter paper disk was immersed in 1 N NaOH / 5 second; filter paper(Whatman No.3) was used because it is easily molded to the cornea when wet. The eyelid was secured in the open position manually. The immersed filter paper disk was placed on the central corneal surface, centered on the pupil and held gently in position for 30 second. Corneal ulcer induced unilateral in each pigeon (figure 1).

Figure (1) Corneal ulcer induced unilateral in each pigeon	Figure (2) the dye around and coats the "tear film" covering the surface of the cornea
--	--

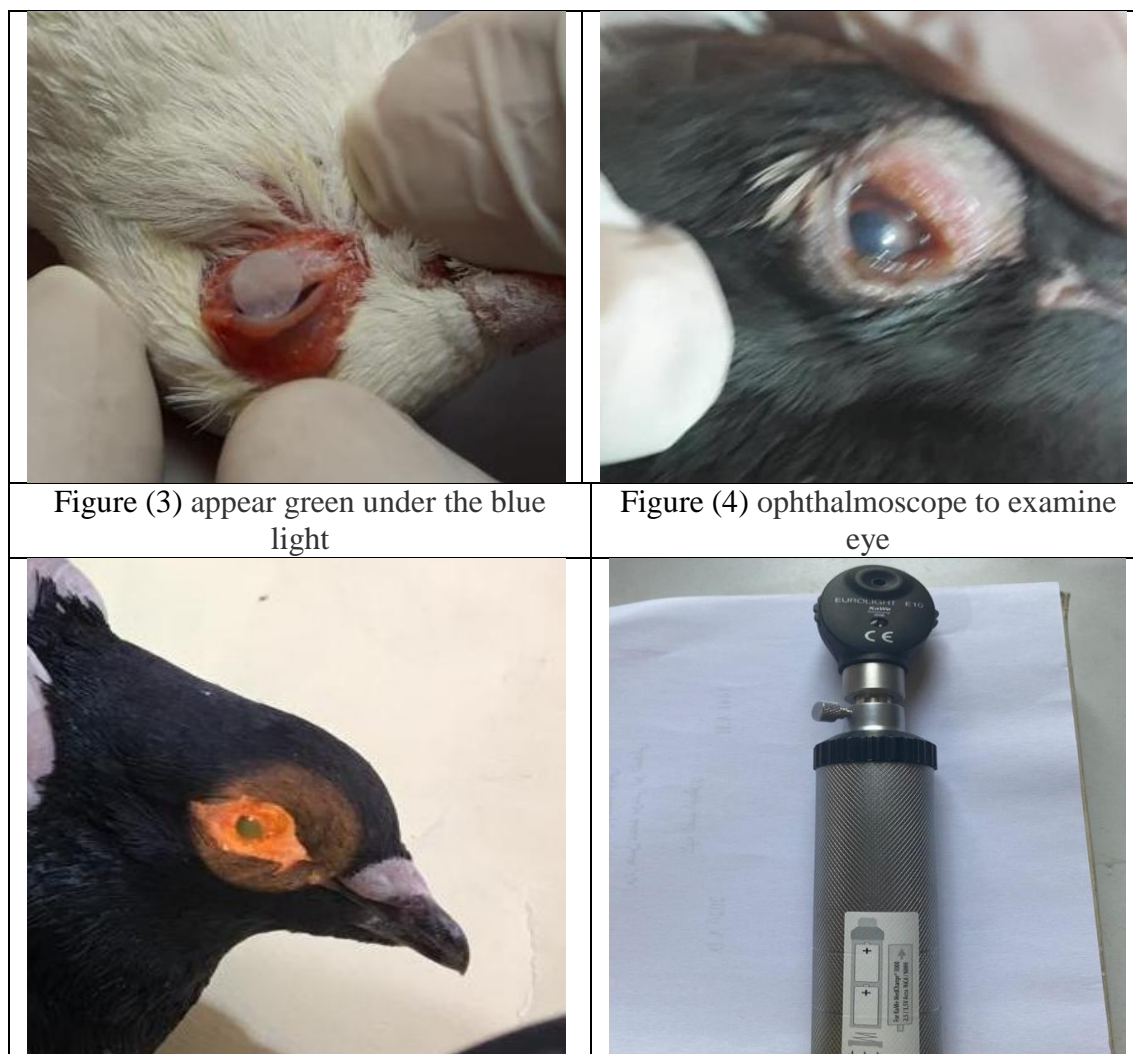

Figure (3) appear green under the blue light

Figure (4) ophthalmoscope to examine eye

Figure (1): filter paper disc saturated with NaOH was induced on the corneal surface of the pigeon.. Corneal ulceration was obvious with lacrimation and eyelids adhesion.

Fluorescent Technique

A piece of blotting paper containing fluorescent dye will be touched to the surface of cornea. Blinking spreads the dye around and coats the "tear film" covering the surface of the cornea (figure 2). By ophthalmoscope a blue light is then directed at rabbit eye. The experimental ulcer on the surface of the cornea will be stained by the dye and appear green under the blue light (figure 3). This test used to determine the size, location, and shape of coronial ulcer depending on the manner of spreading of the dye between the damaged tissues of cornea. Figure 4 ophthalmoscope to examine eye to see ulcer in cornea.

Clinical evaluation

External and detailed ophthalmic examinations of each eye were done once daily. Eyes were examined for the presence of perforation, vascularization, lacrimation, eyelids adhesion, pus, or infection.




Histopathological examination

On the day 10th, 15th, post induced corneal ulcer sacrificing the birds, the entire eye was excised from the head with curved surgical scissor. Eyes were immediately placed in 10% formalin. The samples were sent to a private laboratory, routine tissue processing, the tissues section were stained with Hematoxylin–Eosin (H&E) (Luna,1968).

The Results

Clinical signs

Apricot seeds extract group were gradually recover after 3rd day while gentamicin group were recover after 7th day as well as control group were showed adhesion and granulation tissue.

		
Fig. (5) Eye picture after three day of Apricot seed extract group	Fig. (6) Eye picture after three day of gentamicin group	Fig. (7) Eye picture after three day of control group

Histopathological pictures

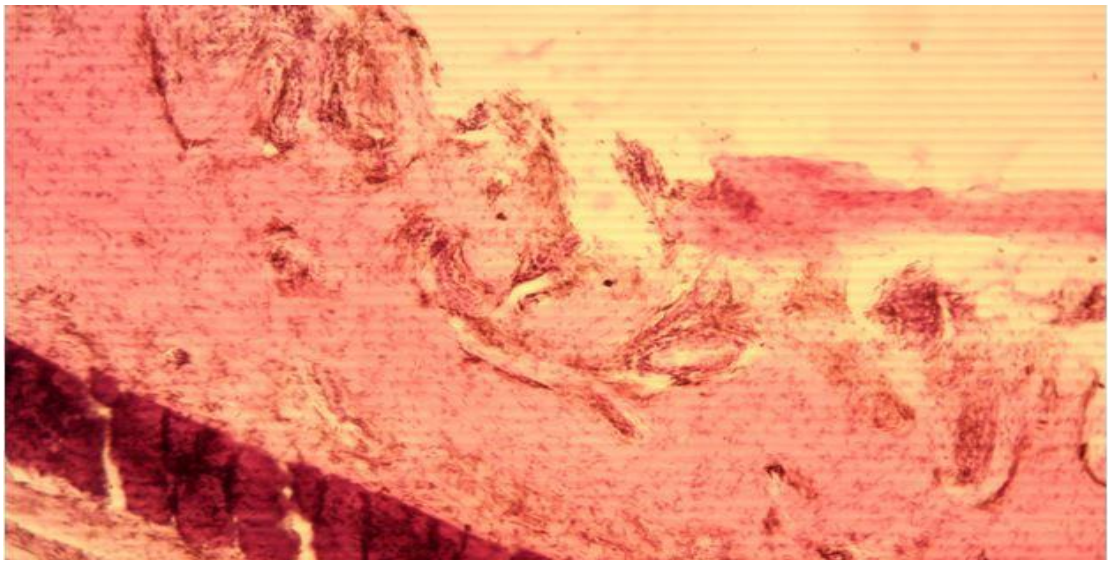


Figure (8): Transverse section of the cornea revealed a deep desquamation of the epithelial layer which shows an absent of squamous and polygonal layer as well to somewhat of Bowman's layer accompanied by the severity of corneal ulceration (black arrows). H&E stain. 10X

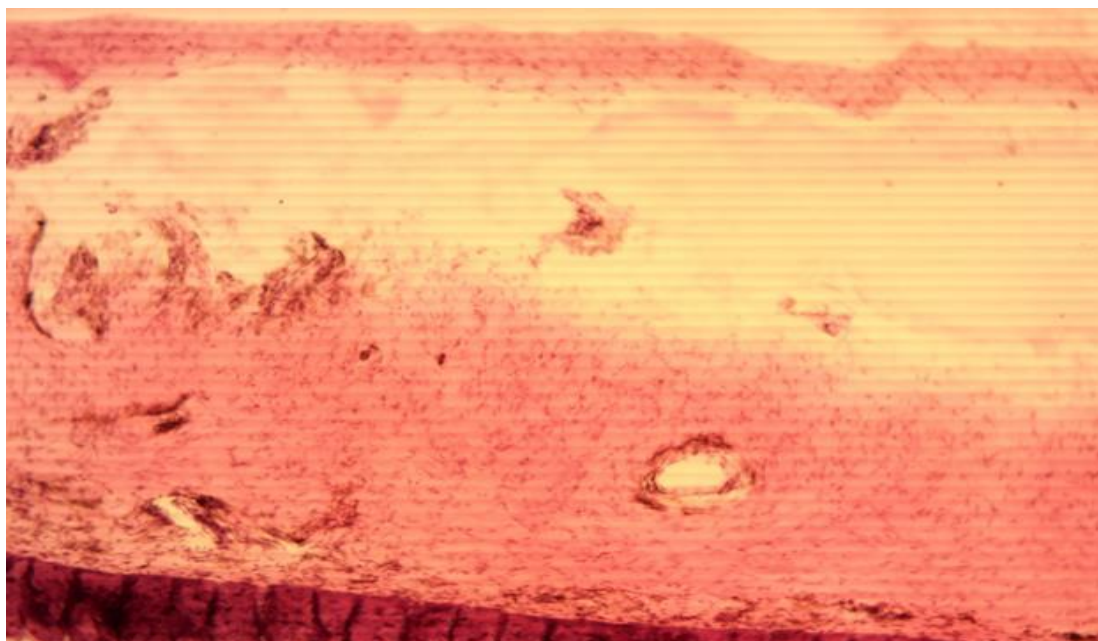


Figure (9): Transverse section of the cornea revealed a degree of corneal regeneration processes of the epithelial layer (black arrow), in addition, there are a complicated edematous fluid formation in the stromal layer of the cornea (blue arrow). H&E stain. 10X

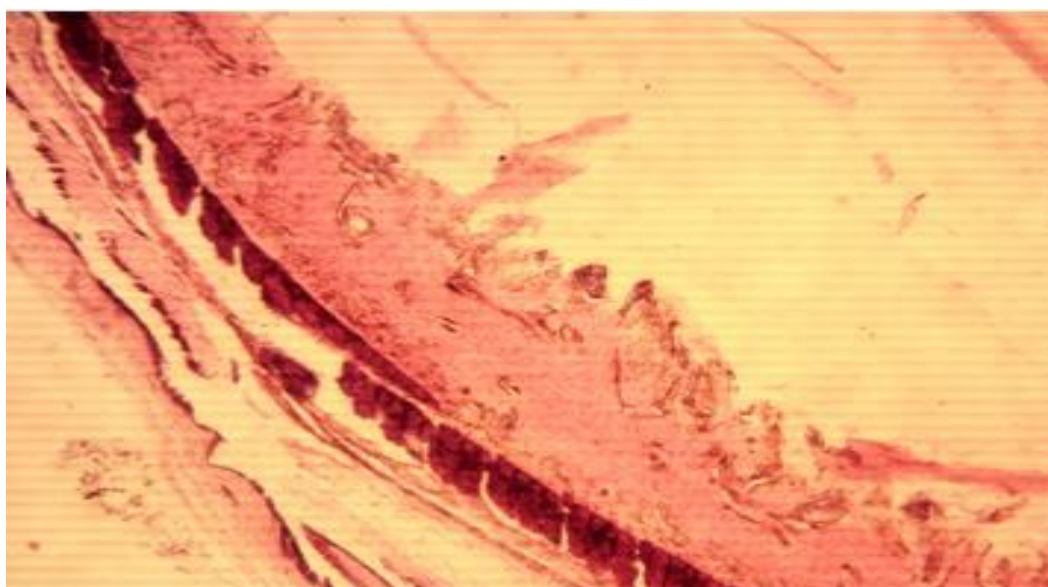


Figure (10): Transverse section of the cornea revealed a noticed regular degree of clean corneal regeneration processes of the epithelial layer (black arrow), in addition, there are a normal architecture of the stromal layer of the cornea (blue arrow). H&E stain. 10X

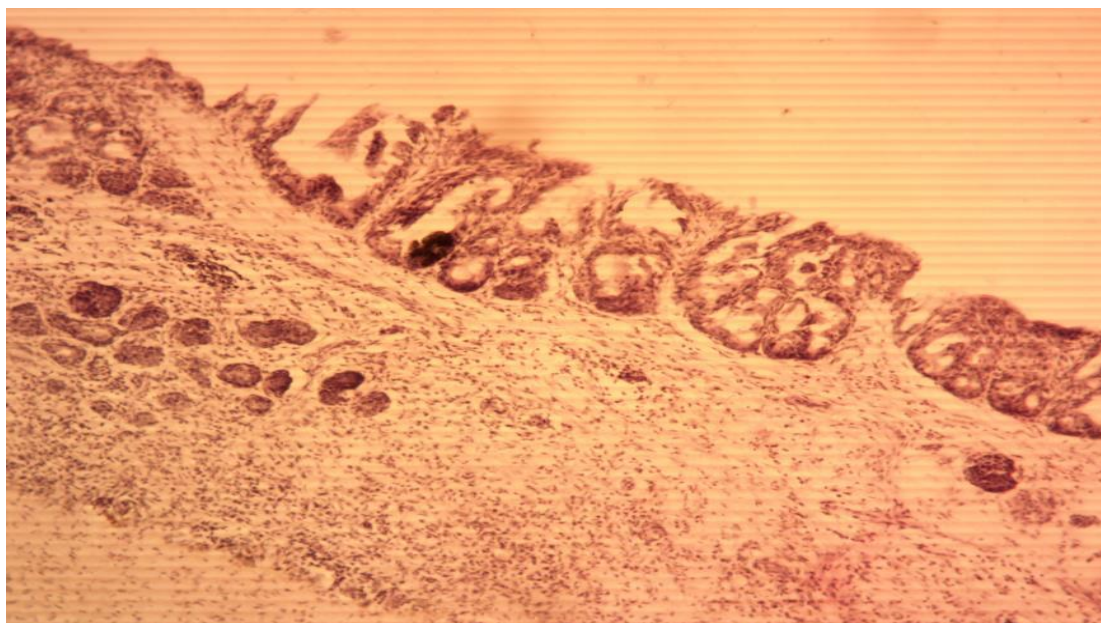


Figure (11): Transverse section of the cornea revealed a degree of corneal regeneration processes of the epithelial layer (black arrow), in addition, there are an inflammatory cells infiltration in the stromal layer of the cornea (blue arrow). H&E stain. 10X

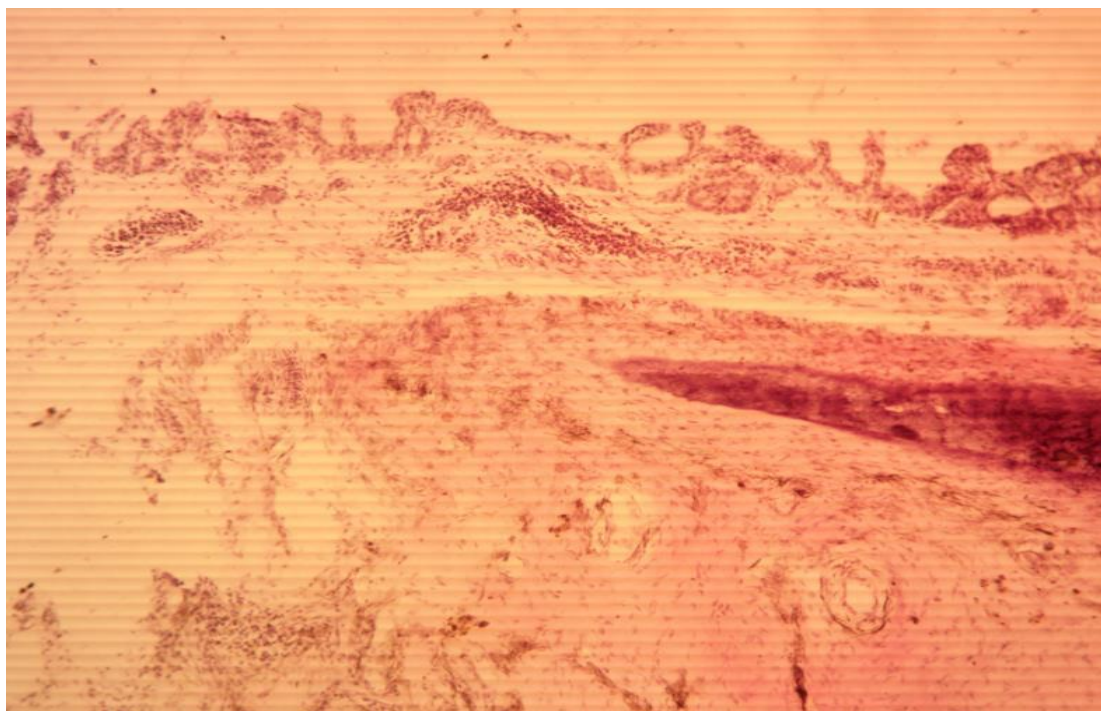


Figure (12): Transverse section of the cornea revealed a delayed corneal regeneration of the epithelial layer (black arrow), in addition, there are an inflammatory cells infiltration in the stromal layer of the cornea as well to noticed granulation tissue formation (blue arrow). H&E stain. 10X

Discussion

Corneal ulcers can be treated with recommended antibiotic eye drops. More severe corneal ulcers

may require stronger, specially together antibiotic drops. Corneal ulcers can cause holes and scarring, leading to serious vision loss (Hyun et al., 2019). The chemical composition of apricot seed plays a major role to treat ulcerative lesion of cornea (Karahane et al., 2005). According to chemical composition and what each one play role to treat and accelerate healing of corneal ulceration. Polyphenols and flavonoids have antimicrobial and antibacterial characteristic against *Pseudomonas*, *Staphylococcus aureus*, and bacteria, Gentamicin is also an effective agent against *Staphylococci* and species of *Streptococci* other than *S. pneumoniae*. It inhibits bacterial protein synthesis via binding to RNA polymerase (Ozcan et al., 2010). On the fifth day after inducing the corneal ulcers, the clinical symptoms of the eyes in both groups that were almost identical due to the same of the lesions showed lacrimation, opacity, but no eyelid adhesion. Caffeic acid phenethyl ester have antiviral and antifungal activity against eye microorganism, Antimicrobial activity is recognized as the most important property of Apricot seed, particularly activity against bacteria. Several studies have been performed to evaluate this property against a large group of Gram-positive and Gram-negative bacteria; both aerobic and anaerobic types (Zhan et al., 2011). Other chemical compositions such as Terpenes, essential oil, and Furfuran lignans also have antimicrobial activity. However, in the gentamicin treated group, clinical results showed notable improvement. Corneal ulcers can range from small epithelial erosions that will heal in less than a week to a descemetocoele that may distract by the end of the day. Treatment of such varied lesions depends on a correct assessment of how deep the ulcer is and whether it is in the process of healing (Farombi et al., 2006). The active compound found in apricot seeds has a stronger and a broad spectrum of antimicrobial activity (Femenia et al., 1995). The antibacterial activity may be indicative of found of some metabolic toxins or broad-spectrum antibiotic compounds, those antimicrobial compounds, phenolic compounds, terpenoids and alkaloids are important in antibiotic effects (Brewer et al., 1994). The antiviral activity of aqueous and ethanol extracts of Apricot seed and constituents, such as flavonoids caffeic acid, p-coumaric acid, benzoic acid, galangin, pinocembrin and chrysin, was tested against herpes simplex virus type 1 (HSV-1) (Huang et al., 2014). Each antibacterial, antifungal and antiviral the first line to treat the ulceration, and prepare to active other composition to heal the ulceration, the second step are the biological and pharmacological activity of the volatile compound of Apricot seed such as terpenes and terpenoid, they have pharmacological activity to treat ulceration of the cornea, these compound have hydro carbonic compound such as Alkan, monostearate, diesters and enzymes such as succinate dehydrocarbonase, glucose-6-phosphate, adenosine triphosphatase, and acid phosphatase, all these compound promote collagen and fibroblast activity to accelerate healing of ulceration and comforted the area to against microbes (Yigit et al., 2009). Gentamicin antibiotic 3% only role against antibacterial and doesn't role in the promotion of collagen and fibroblast activity (Lee et al., 2014). Histopathological changes in gentamicin group were showed intact corneal epithelium while Apricot seed group showed inflammatory cells infiltration compare with control group was showed normal epithelium and stroma, other feature of the Apricot seed of Apricot seed mononuclear cells and white arrow (recovered whole epithelium), these different change due to pharmacological activity of Apricot seed, this results agree with most research such as (Georgiadis et al., 2008). After the 20th day, the two groups did not show apparent differences, as the eyes looked close to normal, meaning that both treatments contribute to protecting and improving the healing of the corneal ulcer. Nevertheless, the gentamicin eye drops did better at improving healing clinical signs. On the day 10th, Histopathological sections of Apricot seed treated corneal tissues showed desquamation of corneal epithelium, edematous stroma with inflammatory cells, and congestion of blood capillaries. but, the antibiotic-treated group showed the intact epithelium and stroma of the cornea with the keratocytes. That is meaning Apricot seed showed a prolonged inflammatory stage or delayed corneal healing.

In conclusion, we can use apricot seed extract solution in the treatment of eye cornea in avian and small animal practice.

References

1. Brewer, M.S., Sprouls G K, and Russon C. (1994). Consumer attitudes toward food safety issues. *J. Food Safety*. 14:63-76.
2. Chen, I.C.; Huang, H.H.; Chen, P.F.; Chiang, H.C. (2016) Sirtuin 3 protects against urban particulate matter-induced autophagy in human bronchial epithelial cells. *Toxicol. Sci*. 152, 113–127.
3. Chipuk JE, Moldoveanu T, Llambi F, Parsons MJ, Green DR. (2010). The BCL-2 family reunion. *Mol Cell* 37:299–310.
4. Doganay S, Duz C, Firat P G, Cankaya C, Kutukde D, Cigremis Y (2013). The effect of apricots on the experimental cataract model formed by sodium selenite. *Food and Chemical Toxicology*. 55 :371-377.
5. Domitrovic' R, Potoc'njak I, Crnc'evic'-Orlic' Z, _Skoda M. (2014). Nephroprotective activities of rosmarinic acid against cisplatin-induced kidney injury in mice. *Food Chem Toxicol* 66:321–328.
6. Ebtehal, H. A. (2011). The cytotoxic effect of apricot seed (*Prunus sarmeniaca*) on human and animal tumor cell line. *Biotechnology research centre-Al-Nahrin University- Iraq*. 6(3): Pp 6-12.
7. Erdogan F, Orhan I, Kartal M, (2010). Insight in to research on phytochemistry and biological activities of *Prunus armeniaca* L.(apricot), *Food Research International*, 44, 152-155.
8. Farombi EO, Ekor M. 2006. Curcumin attenuates gentamicin induced renal oxidative damage in rats. *Food Chem Toxicol* 44: 1443–1448.
9. Feizi, S (2018). Corneal endothelial cell dysfunction: etiologies and management. *Therap. Adv. in Ophth.* 1-19. journals.sagepub.com/home/oed.
10. Femenia, A.. C. Rossello, A. Mulet, J. and Cnellas H (1995). Chemical composition of bitter and sweet apricot kernels. *J. Agric. Food Chem*. 43: 356-361.
11. Georgiadis NS, Ziakas NG, Boboridis KG, (2008). Cryopreserved amniotic membrane transplantation for the management of symptomatic bullous keratopathy. *Clin Exp Ophthalmol*. 36: 130–135.
12. Hyun S, Kim J, Park B, Jo K, Lee T G, Kim J S, Kim C S (2019). Apricot Kernel Extract and Amygdalin Inhibit Urban Particulate Matter-Induced Keratoconjunctivitis Sicca. *Molecules* :24(3):650.
13. Kang WS, Choi H, Jang G, Lee KH, Kim E, Kim KJ, Jeong GY, Kim JS, Na CS, Kim S. (2020). Long-Term Exposure to Urban Particulate Matter on the Ocular Surface and the Incidence of Deleterious Changes in the Cornea, Conjunctiva and Retina in Rats. *Int J Mol Sci.* . 21(14):4976.
14. Karahan I, Atessahin A, Yilmaz S, Cerbisat AO, Sakin F. 2005. Protective effect of lycopene in gentamicin– induced oxidative stress and nephrotoxicity in rats. *Toxicology* 215:198–204.
15. Kim CS, Jo K, Lee IS, Kim J. (2016). Topical Application of Apricot Kernel Extract Improves Dry Eye Symptoms in a Unilateral Exorbital Lacrimal Gland Excision Mouse. *Nutrients*. 8(11):750.
16. Kim, C.S.; Jo, K.; Lee, I.S.; Kim, J. (2016) Topical application of apricot kernel extract improves dry eye symptoms in a unilateral exorbital lacrimal gland excision mouse. *Nutrients*, 8, 750.
17. Lee, H.H.; Ahn, J.H.; Kwon, A.R.; Lee, E.S.; Kwak, J.H.; Min, Y.H. (2014). Chemical composition and antimicrobial activity of the essential oil of apricot seed. *Phytother. Res*. 28: 1867–1872.
18. Luna L G . *Manual of Histological Staining Methods* Blackstone Division, McGraw-Hill, 1968.
19. Nostro, A.; Germano, M. P.; D'angelo, V.; Marino, A.; and Cannatelli, M. A. (2000). Extraction methods and bioautography for evaluation of medicinal plant antimicrobial activity. *Lett. Appl. Microbiol. J*. 30: 379-384.
20. Nout M.J.R. Tunçel G. and Brimer L. (1995). Microbial degradation of amygdalin of bitter apricot seeds (*Prunus armeniaca*). *International Journal of Food Microbiology* 24,(3) : 407-412.
21. Ozcan MM, Ozalp C, Unver A, Arslan D, Dursun N. (2010). Properties of apricot kernel and oils

- as fruit juice processing waste. *Food Nutr. Sci.* **1**, 31-37.
22. Shehan N. A. (2012). Anatomical and histological study of eye in local chickens (*Gallus domesticus*) at Basrah city. *AL-Qadisiya Journal of Vet.Med.Sci.* **7** (2) : 53-59.
23. Yau C W , Busin M , I Avni, H E Kaufman (1986). Antibacterial effect of donor corneas stored in gentamicin-enriched McCarey-Kaufman medium. *Arch Ophthalmol.* ;104(2):263-5.
24. Yigit, D.; Yigit, N.; Mavi, A. (2009). Antioxidant and antimicrobial activities of bitter and sweet apricot (*Prunus armeniaca* L.) kernels. *Braz. J. Med. Biol. Res.* **42**, 346–352.
25. Yu Chen , Jinshu Ma, Fang Wang, Jie Hu, Ai Cui, Chengguo Wei, Qing Yang, Fan Li (2013). Amygdalin induces apoptosis in human cervical cancer cell line HeLa cells. *Immunopharmacol Immunotoxicol.* **35**(1):43-51.
26. Zhang, J.; Gu, H.D.; Zhang, L.; Tian, Z.J.; Zhang, Z.Q.; Shi, X.C.; Ma, W.H.(2011) Protective effects of apricot kernel oil on myocardium against ischemia-reperfusion injury in rats. *Food Chem. Toxicol.* **49**, 3136–3141.