Annals of R.S.C.B., ISSN:1583-6258, Vol. 25, Issue 5, 2021, Pages. 6027 - 6030
Received 15 April 2021; Accepted 05 May 2021.

Impacted Gallbladder Stone in a 7-Year-Old Boy: A Case Report

S. Rajasekaran[1*], Venkatesan K[2], D. Euvalingam[2]

[1]Professor and Director, Department of General Surgery, Sri Lakshmi Narayana Institute of Medical Sciences, Puducherry, India.

[2]Assistant Professor, Department of General Surgery, Sri Lakshmi Narayana Institute of Medical Sciences, Puducherry, India.

***Corresponding author:**

Prof. Dr.S.Rajasekaran MS

Professor of Surgery,

Sri Lakshmi Narayana Institute of Medical Sciences, Puducherry

Phone (or Mobile) No.: 9843454566

Email: s.raseran@gmail.com

ABSTRACT

Gallstones are usually seen in adult patients, A fat, fertile, forty females present more common than males. However, it can be seen in children in rare occasions. There is a common prevalence of gallstones in children suffering from haemolytic Syndromes owing to hyperbilirubinemia. Irrespective of etiology, the usual presentation of these patients is abdominal pain immediately after the meal. Ultrasound remains the cornerstone in diagnosis of gallstones and other gallbladder associated pathology. We present an uncommon but classic case of impacted stone in gallbladder neck wall in a7 year old boy presenting with chronic intermittent abdominal pain. He was treated with open Cholecystectomy. The post operative period was unremarkable and the patient was discharged after 8 days.

Key words: Gall bladder stones, Impacted stone in the gallbladder neck wall, Cholecystectomy.

INTRODUCTION:

There is an increased incidence of gallstones in pediatric patients with haematological disorders [1]. Whereas in adults, the risk of gallstones increases with increase in incidence of obesity. Given the rising incidence of obesity among children in India, it is highly likely that cholelithiasis will also increase in this population with time. There are indeed not many reports available in the literature about impacted gallstones in the pediatric population [2].

CASE PRESENTATION:

A healthy 7 years old, 146cms,30 kg boy came to General Surgery OPD, after multiple visits to other facilities during thesame week with chief complaint of abdominal pain which was postprandial colicky pain andthe child's mother endorsed those similar complaints were present for the past 3 months. The patient denied emesis, jaundice, icterus, pruritus, or any altered mental status. She also gave history of fever spikes the previous day before reaching

Annals of R.S.C.B., ISSN:1583-6258, Vol. 25, Issue 5, 2021, Pages. 6027 - 6030
Received 15 April 2021; Accepted 05 May 2021.

the hospital. On Physical examination patient was found to have tenderness in right hypochondrium with no palpable mass or organomegaly. Laboratory studies showed a normal total bilirubin , and raised leucocytes. USG abdomen and CECT abdomen revealed a distended gallbladder with a calculus of size 1.5x 1 x1cm stone in gallbladder fundus and another impacted gallstone in the gallbladder neck wall of size 1×0.8 × 0.7 cm. (Fig 1,2,3).An elective cholecystectomy was planned, but patient presented with acute symptoms on wee hours of the day of surgery, so an emergency open cholecystectomy was performed and intraoperative findings showed a distended tense gallbladder with omental adhesions , Gallbladder stone was palpable at the fundus and neck of gallbladder , CBD and cystic duct was checked and found to be free of stones ,A retrograde cholecystectomy was performed and abdomen closed in layers(Fig – 4,5). Post operative period was unremarkable and the patient was discharged after 8 days.

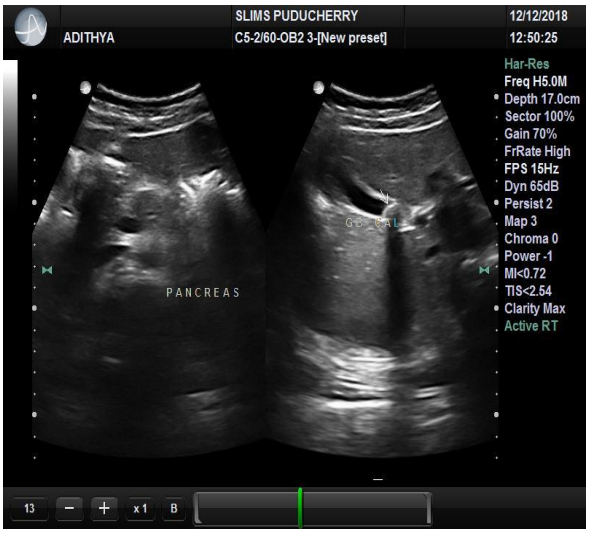

Fig 1 - USG showing a impacted stone in Gallbladder Neck

Fig 2, 3 - CT image showing Gall bladder stone in the Fundus

Annals of R.S.C.B., ISSN:1583-6258, Vol. 25, Issue 5, 2021, Pages. 6027 - 6030
Received 15 April 2021; Accepted 05 May 2021.

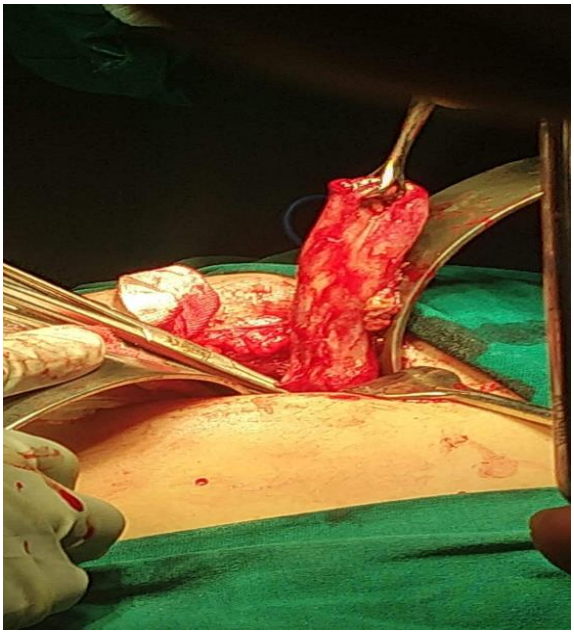

Fig – 4 – Intraoperative findings

Fig – 5- Specimen

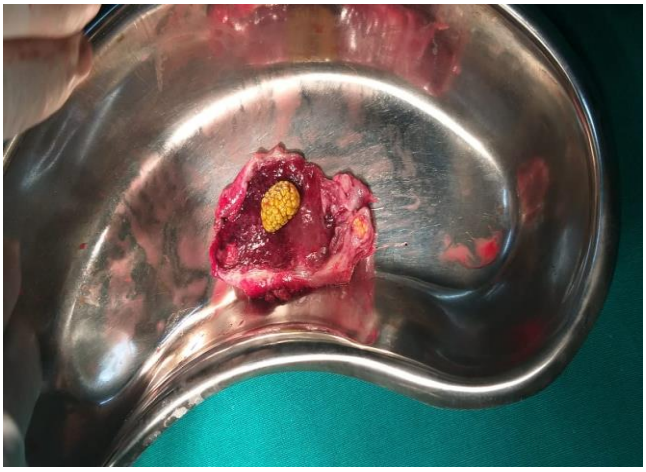

Fig – 6 – Stones in the fundus and neck of the GB

DISCUSSION

Gallstones are not common in children under 15 years comprising only 0.1-0.2% of the incidence of the disease (3). Gallstones occur when there is an imbalance in the chemical constituents' bile acids and phospholipids of bile, which keep cholesterol in solution by the formation of micelles. An excess cholesterol relative to bile acids and phospholipids which allow cholesterol to form as crystals. The incidence of gall stones increases with age and seen with all age groups (4). The bile salts in the bile are important in emulsifying the fat in the intestine and in assisting with its digestion and absorption. Gallstones are pieces of solid material that form in the gall bladder these stones are develop because cholesterol and pigments in bile form hard particles. Two main types of gall stones are cholesterol stones and pigment stones.

Cholesterol stones are usually yellow green color. Pigment stones are smaller and darker and are made up of bilirubin (5). pigment stones are more predominately common, they are

Annals of R.S.C.B., ISSN:1583-6258, Vol. 25, Issue 5, 2021, Pages. 6027 - 6030
Received 15 April 2021; Accepted 05 May 2021.

composed of calcium bilirubinate or polymer like complexes. Recurrent pyogenic cholangio hepatitis are more commonly associated with pigmented gallstones and they are more often seen in the bile duct than in the gall bladder.

Cholelithiasis in children was reported by Gibson in 1737 which was not common in the past(6). However, presently cholelithiasis in children and adolescents is evolving and studies suggest its ever increasing frequency and resultant cholecystectomies at early age15. There is higher incidence of obesity in children and the increased use of USG has a significant effect in the diagnosis of gallstones.

CONCLUSION:

Impacted Gallstone is uncommon in children. Despite its relative rarity in comparison to adults, cholelithiasis must always be the differential diagnosis with a childhood complaining of postprandial abdominal pain. USG and CECT findings remain cornerstone in confirming the diagnosis of this condition. Cholecystectomy is the appropriate treatment for symptomatic cholelithiasis, especially so in children with sickle cell disease or other hemolytic disorders.

Acknowledgement: We would like to thank the staffs of General Surgery department for spending their valuable time and for their co-operation in completing the study.

Funding for the study: Nil

Conflict of interest: Nil

REFERENCES

1. Mehta S, Lopez ME, Chumpitazi BP, Mazziotti MV, Brandt ML, Fishman DS:Clinical characteristics and risk factors for symptomatic pediatricgallbladder disease. Pediatrics 2011, 129:e82–e88.
2. Stinton LM, Myers RP, Shafer EA: Epidemiology of gallstones. GastroenterolClin N Am 2010, 39:157–169.
3. Koebnick C, Smith N, Black MH, Porter AH, Richie BA, Hudson S, Gililland D,Jacobsen SJ: Longstreth GF. Pediatric obesity and gallstone disease:results from a cross-sectional study of over 510,000 youth. J PediatrGastroenterol Nutr 2012. epub ahead of print.
4. Rudisill H: X-ray visualization of a calcified gallstone in a child sevenyears old. Radiology 1931, 16:42–944.
5. Johnston DE, Kaplan MM: Pathogenesis and treatment of gallstones. NEJM1993, 328:412–421.
6. Punia RPS, Garg S, Bisht B, Dalal U, Mohan H: Clinico-pathologicalspectrum of gallbladder disease in children. Acta Paediatr 2010,99:1561–1564.